



(REVIEW ARTICLE)



## Relevance of soft tissues and facial angles in orthodontic diagnosis: A literature review

Karla Teresita Segovia Sigüenza \*, Kevin Lenin Lalangui Felicita, Priscila Elizabeth Patiño Ortíz and Valeria Del Rosio Sigüencia

*Department of Orthodontics, School of Dentistry, University of Cuenca-Ecuador, Cuenca, Ecuador.*

World Journal of Advanced Research and Reviews, 2024, 24(02), 761–768

Publication history: Received on 27 September 2024; revised on 04 November 2024; accepted on 06 November 2024

Article DOI: <https://doi.org/10.30574/wjarr.2024.24.2.3385>

### Abstract

Facial harmony is characterized by the alignment of teeth, bone structures, and soft tissues. During orthodontic treatment, it is essential to consider how the positioning of teeth and jaws impacts the anatomy of soft tissues, a key aspect in diagnosis and aesthetic planning. This article aims to review the most commonly used points and angles in various studies utilizing lateral cephalometry applied to orthognathic surgery analysis, guided extractions, and malocclusion correction. A search of scientific databases yielded 43 relevant studies published in the past five years. Cephalometric analyses and facial angles, such as the nasolabial and Z angles, are crucial for assessing facial aesthetics. Key anatomical landmarks include the Pogonion, upper and lower lips, and the subnasale region, essential for analyzing facial profile and symmetry. Measuring the lips and their relationship to facial structures allows for the evaluation of facial projection and proportion, which are fundamental factors in orthodontic treatments. Finally, this work emphasizes the importance of integrating a three-dimensional approach in clinical training, as the analysis of soft tissue symmetry and proportion is essential for both oral health and facial aesthetics. In conclusion, orthodontists should recognize the importance of these tissues when developing aesthetic treatment plans, ensuring a balance between functionality and aesthetics.

**Keywords:** Soft Tissues Analysis; Cephalometric Analysis; Lateral Radiograph; Orthodontics

### 1. Introduction

Facial harmony is determined by three factors: the alignment of teeth, bone structures, and the characteristics of soft tissues [1]. During orthodontic treatment aimed at achieving aesthetic harmony, it is essential to consider how the position of the teeth and jaws influences the anatomy of soft tissues, which is a fundamental objective in diagnosis, treatment planning, and aesthetic outcomes [1–4]. Soft tissues play a crucial role in the therapeutic plan and in achieving a harmonious facial appearance [5].

The new approach related to soft tissues is primarily based on the study of cephalometrics and facial analysis [2–6]. Cephalometric measurements are conducted using reference points, angles, distances, and measurement proportions. Various parameters exist for the cephalometric analysis of soft tissues, including those established by Legan, Burstone, McNamara, Scheideman, Holdaway, Steiner, Downs, Ricketts, Rakosi, and Schwarz [1,3].

This article aims to review the most commonly used points and angles in the various studies conducted with lateral cephalometry applied to the analysis of orthognathic surgery, guided extractions, and malocclusion correction

\* Corresponding author: Karla Teresita Segovia Sigüenza

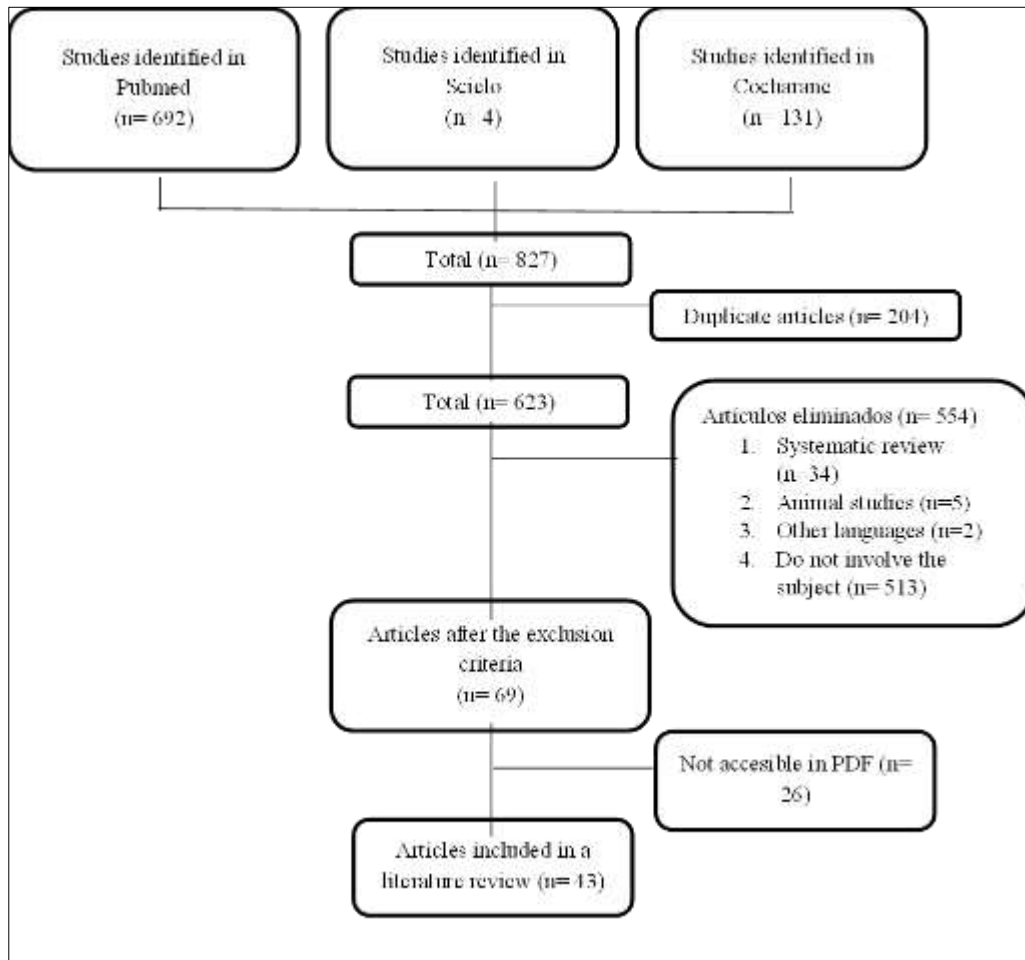
## 2. Material and methods

Scientific articles were selected from three different digital databases: PubMed, Scielo, and Cochrane. The following MeSH terms were used for the collection of scientific articles: “Soft tissues analysis” AND “Cephalometric analysis,” “Soft tissues analysis” AND “Lateral radiograph,” and “Soft tissues analysis” AND “Orthodontics,” published within the last five years (2019-2024) to obtain the most recent articles aligned with our objective.

The reviewed articles included observational studies, comparative studies, randomized clinical trials, and original articles. Only publications in English and Spanish were considered, regardless of the age or sex of the participants. Articles that imposed restrictions on publication data and access were excluded. Duplicates between the databases were removed using Zotero, which also aided in data collection and storage, while Microsoft Excel 2010 was utilized as a database for organizing the articles.

## 3. Results

Upon initiating the search in the digital databases, a total of 827 articles were identified, of which 204 duplicates were excluded. After reviewing titles and abstracts, 513 articles were eliminated. A screening process was conducted, resulting in the exclusion of 26 articles for which the full text was not available, and an additional 41 articles were excluded based on the inclusion and exclusion criteria. Ultimately, a total of 43 articles were obtained. The selection process for the studies is detailed in the flow diagram (Fig. 1).



**Figure 1** Flowchart showing the methodology used in the selection of studies

### 3.1. Cephalometric Points of Soft Tissues

The lateral cephalometric radiograph of the skull is used to evaluate skeletal, dental, and soft tissue components. Cephalometry can be performed conventionally (manually) and/or with computer assistance (digital) [4,7].

Vithanaarachchi et al. (2020) demonstrated that there is no difference between the methods for analyzing linear and angular measurements [4].

In the reviewed articles, the anatomical points most frequently used for the analysis of facial soft tissues include several key areas that allow for the assessment of facial symmetry and proportion. Among the most notable are the soft tissue Pogonion (Pog'), the Upper Lip (Ls), and Lower Lip, as well as the Subnasale (Sn) and Soft tissue Menton (Me'), all of which are essential for analyzing facial profile and projection [2–4,8–14,14–27,27–29]. The Soft tissue Nasion (N') and Soft tissue Glabella (Gl') are crucial points in studies related to the forehead and vertical harmony of the face [2–4,9,10,13,14,18–22,24–27,30].

Additionally, points such as Stomion (Stm), Stomion Superior (Stms), and Stomion Inferior (Stmi) are reference points in analyzing the relationship between the lips and their resting position [2–4,9,13,14,21,22,26,27,31–33]. Furthermore, the Soft tissue Point A (A') and the Soft tissue Point B or Supramentum (B') allow for the evaluation of the relationship between the maxilla and mandible in an aesthetic and functional context [8–10,12,13,15,17,18,22,34].

The Nasal Tip or Pronasale (Prn) is frequently used to assess the aesthetics and proportion of the nose in relation to other facial structures [2,3,13,15,17,19–23,30]. The Columella (Cm) and Soft tissue Gnathion (Gn') also play an important role in the evaluation of overall facial harmony and the maxillomandibular relationship [3,9,10,13,15,26,28,29].

Finally, other points of interest include the Superior Sulcus (Ss) and Inferior Sulcus (Si), which enable the study of facial profile characteristics in key areas for expression and aesthetics [2]. The Cervical Point (C) and Rhinion (Ri) are included in analyses as complements to the relationship between the head and neck, providing additional information in the assessment of facial and postural aesthetics [2,13,14,26]. These points facilitate a comprehensive and detailed analysis of facial balance and aesthetic proportions.

### 3.2. Soft Tissue Angles in Cephalometric Analysis

In studies of cephalometric and facial aesthetic analysis, certain angles are key to evaluating both the aesthetics and the functional relationship and proportion of facial structures. Among these angles is the Nasolabial Angle (Cm – Sn - Ls), which is one of the most commonly used to determine the relationship between the upper lip and the nose, assisting in the evaluation of the profile and nasal aesthetics [9,14,19,20,25,30,32,35,36]. The Z Angle (FH – Me' Labial Prominence) is another relevant measurement for analyzing the overall projection of the face [7,16,20,37–39], while the Facial Angle (FH – N' Pog') focuses on the general inclination of the facial profile, providing an overview of the balance between hard and soft structures [7,15,20,24,25]. The H Angle (N' Pog' - Ls Me') assesses the relationship between the lower lip and the H line, allowing for the measurement of the projection of the mandible and chin [15,24,25].

The Facial Convexity Angle (Gl' -Sn - Pog'), LCTA (Li - Pog' - C), and the Mentolabial Angle (Li - B' - Pog') are fundamental for analyzing the curvature of the profile in the lower region of the face, particularly in the chin and mandible area [7,19,29,29,31,32,35]. Other important angles include that from Point B to Nasion and Pogonion (B' - N' - Pog'), which aid in studying the relationship between the forehead, nose, and chin [18]. The Nasomental Angle (N' - Prn - Pog') is used to examine the relationship between the nose and chin, providing information about profile harmony [7,30].

Finally, angles such as the Soft Tissue Convexity (N' - Sn - Pog') are included, which analyze the projection of the lower lip and the overall shape of the face [30,31]. Other relevant points include the distance from the Nasal Tip to the H line (Prn - Ls Me'), the Nasal Tip Angle (N' - Prn - Sn), and the Nasofrontal Angle (Gl' - N' - Prn), which allow for the assessment of nasal projection [13,24,40,41]. Meanwhile, the Superior Lip Angle (Tangent Ls - Vertical Line of Sn) and the Inter labial Angle (Ls - Stm - Li) provide a detailed evaluation of the projection and shape of the lips in lip aesthetics [19,25]. The total facial convexity angle (Gl' - Prn - Pog) offers a broader view of facial harmony, integrating the relationships among multiple facial structures to provide a comprehensive evaluation of the aesthetic balance of the face [19].

### 3.3. Soft Tissue Measurements in Cephalometric Analysis

In the analysis of facial profiles and proportions, some of the most utilized measurements focus on the relationship between the lips and key facial structures. The Measurement of the Upper and Lower Lips in relation to the E line (Ls – E Line) (Li – E Line) and the Thickness from Pogonion to Soft Tissue Pogonion (Pog – Pog') are essential for evaluating the facial profile and the projection of the mandible, providing valuable information about facial harmony [7,13,16,21–23,26,28,29,37,40,42,43]. The Thickness of the Upper Lip (BerS. – Is1) and its position in relation to the E line (Ls – E Line) are other critical points for analyzing lip proportion [7,9,15,16,21,23,34,35,37,40]. Additionally, the Thickness of

the Hard and Soft tissue Menton (Me-Me') is used to examine symmetry between skeletal structures and soft tissues of the chin [13,15,22,24,26,43].

Other relevant measurement points include the Basic Thickness of the Upper Lip (A- Ls), Basic Thickness of the Lower Lip (B - Li), and the S Line to the Upper Lip (Ls - Pog' half base of the nose) and Lower Lip (Li - Pog' half base of the nose), along with the Inter labial Measurement (Ls - Li), which provide key information about lip aesthetics and functionality [7,9,15,19,21,25,34,35]. The Protrusion of the Upper Lip (Ls-Sn-Pog) is an essential metric for determining lip projection in relation to the Subnasale and Pogonion [4,9,35], as well as the distance from Subnasale to the H Line (Sn - H Line), the Length of the Upper Lip (StmS - ENA), and its relation to the maxillary incisor (Is1-Ls), It is deduced that the change in soft tissues corresponds to one-third of the change in tooth position [9,13,15,21,22,24,42]. However, the thickness of the lips is notably significant; the more voluminous they are, the less they tend to adjust to this modification [12].

Regarding the projection of facial structures, the Protrusion of the Lower Lip in relation to the Subnasale and Pogonion (Li-Sn-Pog) and the Nasal Prominence (FH - BerS - Prn) are essential for defining the middle third of the face [4,9,15,16]. Likewise, the Height of the Lower Third (Sn-Me'), the Length of the Lower Lip (Stm - Me'), and the relationship of the Lower Lip with the H Line (Li - H Line) are important for examining the projection of the lip and mandible [15,21,21,25]. The Depth of the Upper Lip Groove (FH - BerS - sLs) and the Lower Lip Groove (H Line - BerI - sLi) are evaluated, along with measurements from Glabella to Soft tissue Glabella (Gl - Gl'), Nasion to Soft tissue Nasion (N - N'), Rhinion to Soft tissue Rhinion (Ri - Ri'), Subspinal to Subnasale (Ss - Sn), Point B to Supramentum (B - B'), and Gnathion to Soft tissue Gnathion (Gn - Gn'), which contribute to analyzing symmetry and proportion between soft and hard tissues [7,13,15,26,28,30].

The skeletal pattern influences the thickness of soft tissue; therefore, when making a change during surgical-orthodontic treatment, the cephalometric reference points are altered, resulting in a change in tissue thickness and a new facial profile [13,14,17].

The tissue thickness established by Holdaway helps us identify soft tissue patterns associated with skeletal malocclusions, such as the protrusion of the upper lip and a convex facial profile resulting from Class II malocclusion, or a thin upper lip and a more prominent lower lip, presenting a concave facial profile due to Class III malocclusion [13,15,17]. The relationship between the maxillary incisor and the upper lip (Is1 - Ls) and the mandibular incisor with the lower lip (Ii1 - Li) provides valuable information about the interaction between the teeth and the surrounding soft tissues [13,21,24,42].

Lastly, other measurements such as the Mentolabial Groove (B' - Li Pog'), the Point A to Subnasale (A- Sn), the Point B of the Mentolabial Groove (B - Lm), and the tension of the upper lip (BerS - Surface of Labial Is1), among others, allow for a detailed evaluation of the balance between the skeletal structure and soft tissues [9,24,42], including measurements such as Pronasale - Subnasale (Prn - Sn Vertical), Upper Lip to Subnasale (Ls - Sn Vertical), and Pogonion to Subnasale (Pog' - Sn Vertical) measured in mm, which provide equilibrium of the lower third of the face and general facial symmetry [21]. These measurements offer a comprehensive view of the relationship between the different parts of the face, being useful in orthodontic and surgical treatments to enhance facial aesthetics.

---

#### 4. Discussion

The comparative study of facial characteristics, such as the upper and lower lips in relation to various reference lines, is crucial for understanding variations in dental and soft tissue morphology [23,29,37]. This analysis includes the Nasolabial Angle, Nasal Prominence, the Sn - Pog' relationship, Upper and Lower Lip Protrusion, Facial Convexity Angle, and Soft Tissue Thickness, which are fundamental elements in orthodontic and surgical planning. Accuracy in measuring these structures allows for the customization of treatments, ensuring an individualized approach for each patient [8,15,35,43].

The relevance of reference points and angular measurements also underscores the interconnection between hard and soft structures. For example, analyzing lip thickness and its relationship with the Facial and Mentolabial Angles provides a clear view of how changes in soft tissues correlate with modifications in skeletal structure [15,21,24,28,32,36]. This is particularly relevant in the context of orthodontic and surgical treatments, where a multidimensional approach can influence aesthetic and functional outcomes [2,12,17]. Identifying patterns such as the protrusion of the upper lip in relation to skeletal malocclusions can assist in personalizing treatments, thus optimizing patients' facial profiles [7,14,16,17].

Consequently, research on the depth of labial grooves and facial proportions, such as vertical height and the relationships between hard and soft tissues, provides valuable insights into facial development [15,24,25,32]. Establishing reference values and ethnic differences in these measures is essential for optimizing aesthetic and functional outcomes in orthodontic and reconstructive procedures [24]. The combination of cephalometric analysis and soft tissue evaluations fosters a comprehensive understanding of facial anatomy.

Perroti et al. (2023) conducted a study comparing 3D and 2D measurements, finding that the accuracy between both methods is significant [3]. They indicate that the main source of error in cephalometric evaluation lies in the incorrect identification of reference points. Therefore, they emphasize that knowledge of 3D anatomy should be integrated into academic training and applied practically [3,13,16,27].

Finally, findings regarding symmetry and proportion in soft tissues highlight the need for comprehensive analysis in clinical practice. The points and angles analyzed are not only important from an aesthetic perspective but also influence masticatory function and overall oral health [1,10,32]. Combining cephalometry with a three-dimensional imaging-based approach, such as computed tomography, can provide a more accurate diagnosis and facilitate more effective surgical planning [3,13,16,27]. In summary, these results reinforce the importance of implementing a comprehensive approach in the analysis and treatment of facial alterations, thus ensuring an appropriate balance between aesthetics and functionality.

### Abbreviations

Superior Lip = Ls, Inferior Lip = Li, Subnasale = Sn, Pogonion = Pog, Soft Tissue Pogonion = Pog', Menton = Soft Tissue Menton = Me', Soft Tissue Nasion = N', Soft Tissue Glabella = Gl', Stomion = Stm, Superior Stomion = StmS, Inferior Stomion = StmI, Point A = A, Soft Tissue Point A = A', Point B = B, Soft Tissue Point B = B', Nasal Tip or Pronasale = Prn, Columella = Cm, Gnathion = Gn, Soft Tissue Gnathion = Gn', Superior Groove = Ss, Inferior Groove = Si, Cervical = C, Rinon = Ri, Soft Tissue Rinon = Ri', Frankfurt Plane = FH, Anterior Nasal Spine = ENA, Maxillary Incisor = Is1, Upper Vermilion = BerS, Lower Vermilion = BerI, Superior Labial Groove = sLs, Inferior Labial Groove = sLi, Subspinal = Ss, Mandibular Incisor = Ii1, Mentolabial = Lm.

---

## 5. Conclusion

General dentists and orthodontists must recognize the relevance of soft tissues in facial profiles, as their impact is fundamental when designing an aesthetic treatment plan following orthodontics. We should not underestimate their importance in enhancing facial appearance.

The key anatomical points and angular measurements identified are essential for assessing facial harmony, highlighting the utility of references such as the Pogonion (Pog'), Nasion (N'), and upper lip (Ls'), among others, for analyzing the proportion and projection of the face. Additionally, cephalometric analysis includes crucial angles, such as the nasolabial angle (Cm - Sn - Ls), the Z angle (FH - Me' Lip Prominence), and the Facial Convexity Angle (Gl' - Sn - Pog'), which are essential for understanding the relationship between hard structures and soft tissues. This comprehensive analysis contributes to diagnosis and treatment in orthodontics and facial surgery, allowing us to understand how changes in soft tissues, influenced by skeletal patterns, affect facial profiles and aesthetic balance

---

## Compliance with ethical standards

### Disclosure of conflict of interest

No conflict of interest to be disclosed.

---

## References

- [1] Ho TTT, Luong QT. Dental-craniofacial Characteristics of Southern Vietnamese People with Well-balanced Face on Cephalometric Films and Its Comparison with Caucasians and Northern Vietnamese Population. *J Int Soc Prev Community Dent.* 2021 Jun 10;11(3):316-323. doi: 10.4103/jispcd.JISPCD\_13\_21. PMID: 34268194; PMCID: PMC8257018.
- [2] Shahamfar M, Atashi MHA, Azima N. Soft Tissue Esthetic Changes Following a Modified Twin Block Appliance Therapy: A Prospective Study. *Int J Clin Pediatr Dent.* 2020 May-Jun;13(3):255-260. doi: 10.5005/jp-journals-10005-1759. PMID: 32904097; PMCID: PMC7450202.

- [3] Perrotti G, Goker F, Rossi O, Nowakowska J, Russillo A, Beltramini G, Tartaglia GM, Testori T, Del Fabbro M, Mortellaro C. 3D Computed Tomography vs. 2D radiography: comparison of 3D direct anthropometry with 2D norm calculations and analysis of differences in soft tissue measurements. *Eur Rev Med Pharmacol Sci.* 2023 Apr;27(3 Suppl):46-60. doi: 10.26355/eurrev\_202304\_31321. PMID: 37129335
- [4] Vithanaarachchi N 5th, Chandrasiri A C, Nawarathna L N. A comparison of cephalometric measurements obtained using conventional and digital methods. *Ceylon Med J.* 2020 Sep 30;65(3):39-45. doi: 10.4038/cmj.v65i3.9184. PMID: 34800930.
- [5] Lee J, Kim D, Xu X, Kuang T, Gateno J, Yan P. Predicting Optimal Patient-Specific Postoperative Facial Landmarks for Patients with Craniomaxillofacial Deformities. medRxiv [Preprint]. 2023 Dec 14:2023.12.13.23299919. doi: 10.1101/2023.12.13.23299919. Update in: *Int J Oral Maxillofac Surg.* 2024 Nov;53(11):934-941. doi: 10.1016/j.ijom.2024.05.004. PMID: 38187692; PMCID: PMC10767768.
- [6] Cheng B, Mohamed AS, Habumugisha J, Guo Y, Zou R, Wang F. A Study of the Facial Soft Tissue Morphology in Nasal- and Mouth-Breathing Patients. *Int Dent J.* 2023 Jun;73(3):403-409. doi: 10.1016/j.identj.2022.09.002. Epub 2022 Oct 8. PMID: 36220699; PMCID: PMC10213793.
- [7] Ankita Agrawal, Narendra Sharma, Ranjit Kamble, Sunita Shrivastav, Shriya Prakash Murarka, Akanksha Kumar. Comparative evaluation of Skeletal, Dental and Soft Tissue Changes in Class II Division 1 Malocclusion Cases Treated with Twin Block and innovative Clear Block Appliance- a Prospective Interventional Study. *Int. J. Res. Pharm. Sci.* [Internet]. 2021 Apr. 16;12(2):1238-46. Available from: <https://ijrps.com/home/article/view/152>
- [8] Rupperti S, Winterhalder P, Krennmair S, Holberg S, Holberg C, Mast G, Rudzki I. Changes in the facial soft tissue profile after maxillary orthognathic surgery. *J Orofac Orthop.* 2022 May;83(3):215-220. doi: 10.1007/s00056-021-00294-2. Epub 2021 Apr 21. PMID: 33881549; PMCID: PMC9038810.
- [9] Alqahtani ND, Alqasir A, Al-Jewair T, Almoammar K, Albarakati SF. Dental and soft tissue changes following extraction of second premolars in females with bimaxillary protrusion: A retrospective study. *Niger J Clin Pract.* 2020 Aug;23(8):1110-1119. doi: 10.4103/njcp.njcp\_636\_19. PMID: 32788489.
- [10] Mehta SY, Han MD, Tsay TP, Kusnoto B. Accuracy of Patient-specific Soft-tissue Prediction Algorithms for Maxillomandibular Surgery in Class III Patients. *Contemp Clin Dent.* 2022 Jul-Sep;13(3):242-248. doi: 10.4103/ccd.ccd\_913\_20. Epub 2022 Sep 24. PMID: 36213849; PMCID: PMC9533383.
- [11] Alhumadi A, Al-Khafaji TJ, Hussein Alyassiri AM, Alhamadi WW. Gender differences in lower facial soft tissue thickness among different skeletal patterns, based on soft tissue cephalometric analysis. *J Orthod Sci.* 2022 Oct 13;11:54. doi: 10.4103/jos.jos\_38\_22. PMID: 36411805; PMCID: PMC9674943.
- [12] Koniarova Z, Husarova R, Stefkova M, Spidlen M, Statelova D, Janickova M, Koniarova A. Improving lip aesthetics in the face profile after treatment of class II, division 2 malocclusion. *Bratisl Lek Listy.* 2022;123(3):185-190. doi: 10.4149/BLL\_2022\_030. PMID: 35343750.
- [13] Alhazmi N, Alrasheed F, Alshayea K, Almubarak T, Alzeer B, Alorf MS, Alshantqiti A, Albalawi M. Facial Soft Tissue Characteristics Among Sagittal and Vertical Skeletal Patterns: A Cone-Beam Computed Tomography Study. *Cureus.* 2023 Aug 31;15(8):e44428. doi: 10.7759/cureus.44428. PMID: 37791214; PMCID: PMC10543933.
- [14] Guo JX, Xu X, Fan L, Pan YC. Facial soft tissue characteristics of patients with different types of malocclusion. *BMC Oral Health.* 2024 Oct 3;24(1):1173. doi: 10.1186/s12903-024-04912-4. PMID: 39363251; PMCID: PMC11451189.
- [15] Zhang X, Mei L, Yan X, Wei J, Li Y, Li H, Li Z, Zheng W, Li Y. Accuracy of computer-aided prediction in soft tissue changes after orthodontic treatment. *Am J Orthod Dentofacial Orthop.* 2019 Dec;156(6):823-831. doi: 10.1016/j.ajodo.2018.11.021. PMID: 31784016.
- [16] Middha A, Shah YD, Gupta S, Syed FA, Rv H, Nashiroddin M. A Comparative Analysis of Treatment Effects of PowerScope and AdvanSync2 in Class II Division 1 Malocclusion: A Retrospective Study. *Cureus.* 2023 Nov 20;15(11):e49105. doi: 10.7759/cureus.49105. PMID: 38125227; PMCID: PMC10732095.
- [17] Lu W, Song G, Sun Q, Peng L, Zhang Y, Wei Y, Han B, Lin J. Analysis of facial features and prediction of lip position in skeletal class III malocclusion adult patients undergoing surgical-orthodontic treatment. *Clin Oral Investig.* 2021 Sep;25(9):5227-5238. doi: 10.1007/s00784-021-03830-x. Epub 2021 Feb 15. PMID: 33590299.
- [18] Chu J, Basyuni S, Moore S, Ferro A, Chang C, Patel K, Jeremiah H, Brassett C, Santhanam V. A Novel Cephalometric Approach Aiming to Quantify a Normal Range of Bony Chin Protrusion. *J Maxillofac Oral Surg.* 2023

- Mar;22(1):226-231. doi: 10.1007/s12663-022-01784-5. Epub 2022 Dec 13. PMID: 36703669; PMCID: PMC9871108.
- [19] Ahmed A, Fida M, Sukhia RH. Cephalometric predictors for optimal soft tissue profile outcome in adult Asian class I subjects treated via extraction and non-extraction. A retrospective study. *Int Orthod*. 2021 Dec;19(4):641-651. doi: 10.1016/j.ortho.2021.08.002. Epub 2021 Aug 24. PMID: 34452856.
- [20] İzgi E, Pekiner FN. Comparative Evaluation of Conventional and OnyxCeph™ Dental Software Measurements on Cephalometric Radiography. *Turk J Orthod*. 2019 Jun;32(2):87-95. doi: 10.5152/TurkJOrthod.2019.18038. Epub 2019 Jun 1. PMID: 31294411; PMCID: PMC6605879.
- [21] Zhou X, Zheng Y, Zhang Z, Zhang Z, Wu L, Liu J, Yang W, Wang J. Customized maxillary incisor position relative to dentoskeletal and soft tissue patterns in Chinese women: A retrospective study. *Korean J Orthod*. 2022 Mar 25;52(2):150-160. doi: 10.4041/kjod.2022.52.2.150. PMID: 35321954; PMCID: PMC8964466.
- [22] Pérez-G Marcelo, Carreño-L Susana, Araya-Díaz Pamela, Parada-I Juan Guillermo, Palomino-M Hernán, Martínez-R Vicente et al . Determinación de Valores de Armonía del Perfil Facial en la Población Chilena. *Int. J. Odontostomat*. [Internet]. 2021 Mar [citado 2024 Nov 03] ; 15( 1 ): 137-144. Disponible en: [http://www.scielo.cl/scielo.php?script=sci\\_arttext&pid=S0718-381X2021000100137&lng=es](http://www.scielo.cl/scielo.php?script=sci_arttext&pid=S0718-381X2021000100137&lng=es). <http://dx.doi.org/10.4067/S0718-381X2021000100137>.
- [23] Jeon S, Lee KC. Comparison of cephalometric measurements between conventional and automatic cephalometric analysis using convolutional neural network. *Prog Orthod*. 2021 May 31;22(1):14. doi: 10.1186/s40510-021-00358-4. PMID: 34056670; PMCID: PMC8165048.
- [24] Nitya K, Madhushankari GS, Narayan KV, Basandi PS, Ramya R, Vasumathi D. Ethnic-Guided Soft Tissue Cephalometric Analysis on Lambani Indian Inhabitants for Forensic Facial Reconstruction. *Cureus*. 2022 Mar 23;14(3):e23430. doi: 10.7759/cureus.23430. PMID: 35475086; PMCID: PMC9031482.
- [25] Murugesan A, Ramasamy N, Harikrishnan S. Soft Tissue Responses to Orthodontic Treatment: Impact of Premolar Extraction on Diverse Growth Patterns. *Cureus*. 2024 Apr 11;16(4):e58077. doi: 10.7759/cureus.58077. PMID: 38738154; PMCID: PMC11088714.
- [26] Buyuk SK, Genc E, Simsek H, Karaman A. Analysis of facial soft tissue values and cranial skeletal widths in different body mass index percentile adolescent subjects. *Cranio*. 2019 Jul;37(4):223-230. doi: 10.1080/08869634.2017.1420440. Epub 2018 Jan 10. PMID: 29318946.
- [27] Kim HJ, Noh HK, Park HS. Differences in facial soft tissue deviations in Class III patients with different types of mandibular asymmetry: A cone-beam computed tomography study. *Korean J Orthod*. 2023 Nov 25;53(6):402-419. doi: 10.4041/kjod23.106. Epub 2023 Sep 7. PMID: 37989577; PMCID: PMC10663576.
- [28] Sodawala J, Akolkar A, Sodawala F, Gandhi S, Hamdani S, Ali SM. Comparison of soft tissue chin thickness at different levels of chin in subjects with various growth patterns. *Indian J Dent Res*. 2020 Mar-Apr;31(2):224-228. doi: 10.4103/ijdr.IJDR\_389\_17. PMID: 32436901.
- [29] Jha K, Adhikari M. Effects of modified twin block appliance in growing Class II high angle cases: A cephalometric study. *F1000Res*. 2024 Apr 23;11:459. doi: 10.12688/f1000research.109040.2. PMID: 38680231; PMCID: PMC11053348.
- [30] Jankowska A, Janiszewska-Olszowska J, Grocholewicz K. Nasal Morphology and Its Correlation to Craniofacial Morphology in Lateral Cephalometric Analysis. *Int J Environ Res Public Health*. 2021 Mar 16;18(6):3064. doi: 10.3390/ijerph18063064. PMID: 33809695; PMCID: PMC8002216.
- [31] Akan B, Veli İ. Evaluation of soft-tissue changes in young adults treated with the Forsus fatigue-resistant device. *Am J Orthod Dentofacial Orthop*. 2020 Apr;157(4):481-489.e2. doi: 10.1016/j.ajodo.2019.05.014. PMID: 32241355.
- [32] Khan AR, Fida M, Sukhia RH. Factors affecting changes in soft tissue profile after various treatment modalities for skeletal Class II malocclusion: A cross-sectional study. *Int Orthod*. 2019 Sep;17(3):497-505. doi: 10.1016/j.ortho.2019.06.009. Epub 2019 Jun 27. PMID: 31257136.
- [33] 33. Niño-Sandoval TC, Vasconcelos BC. Biotypic classification of facial profiles using discrete cosine transforms on lateral radiographs. *Arch Oral Biol*. 2021 Nov;131:105249. doi: 10.1016/j.archoralbio.2021.105249. Epub 2021 Aug 27. PMID: 34543809.

- [34] Abirami S, Jain RK. Soft tissue upper lip thickness in different skeletal malocclusion subjects - A comparative cephalometric study. *Indian journal of forensic medicine and toxicology*, 2020, 14(4), 5706-5712. <https://doi.org/10.37506/ijfmt.v14i4.12504>
- [35] Lingeshbabu Pawar A, Basavapattana Shivasubramanya J, Kolothu Parambil S, Shivamoga Raju A, Debata A. Cephalometric Analysis of Hard and Soft Tissue Changes Following Anterior Maxillary Osteotomy Distraction in Cleft Maxillary Hypoplasia. *J Maxillofac Oral Surg*. 2021 Dec;20(4):680-688. doi: 10.1007/s12663-020-01404-0. Epub 2020 Sep 1. PMID: 34776703; PMCID: PMC8554913.
- [36] Gołębiowski M, Świątkowska A, Pastuszek P, Rahnema M. Relationship between Selected Cephalometric Parameters, Nasolabial Angle and Its Components in Adolescent Females. *Diagnostics (Basel)*. 2023 Mar 22;13(6):1199. doi: 10.3390/diagnostics13061199. PMID: 36980507; PMCID: PMC10047291.
- [37] Yuan J, Zhuang Z, Niu L, Zhang Y, Cui S, Su H, Chen G, Zhang X, Han B, Chen S. A comparative study on anterior teeth retraction-related hard and soft tissue changes with physiologic anchorage control technique. *Eur J Med Res*. 2024 Feb 9;29(1):110. doi: 10.1186/s40001-024-01670-5. PMID: 38336775; PMCID: PMC10854088.
- [38] Ardani IGAW, Dinata FC, Triwardhani A. The Importance of the Occlusal Plane in Predicting Better Facial Soft Tissue in Class II Malocclusion in Ethnic Javanese. *Eur J Dent*. 2020 Jul;14(3):429-434. doi: 10.1055/s-0040-1713331. Epub 2020 Jun 26. PMID: 32590869; PMCID: PMC7440935.
- [39] Radwan ES, Maher A, Montasser MA. Comparative Evaluation of Twin Block Appliance and Fixed Orthodontic Appliance in Early Class II Malocclusion Treatment: A Randomized Controlled Trial. *J Contemp Dent Pract*. 2022 Nov 1;23(11):1111-1121. doi: 10.5005/jp-journals-10024-3426. PMID: 37073934.
- [40] Ponnamma S, Reddy G, Muddaiah S, Somaiah S, Shetty BK. An evaluation of dentofacial changes in Angle's class II division 1 patients using AdvanSync 2. *J Orthod Sci*. 2023 Mar 18;12:17. doi: 10.4103/jos.jos\_44\_22. PMID: 37351416; PMCID: PMC10282522.
- [41] Akan B, Veli İ. Evaluation of soft-tissue changes in young adults treated with the Forsus fatigue-resistant device. *Am J Orthod Dentofacial Orthop*. 2020 Apr;157(4):481-489.e2. doi: 10.1016/j.ajodo.2019.05.014. PMID: 32241355.
- [42] Choi SH, Lee H, Hwang JJ, Jung HD, Hwang CJ, Cha JY. Differences in soft-tissue thickness changes after bimaxillary surgery between patients with vertically high angle and normal angle. *Am J Orthod Dentofacial Orthop*. 2021 Jan;159(1):30-40. doi: 10.1016/j.ajodo.2019.10.028. Epub 2020 Oct 27. PMID: 33127204.
- [43] Bral A, Olate S, Zaror C, Mensink G, Coscia G, Mommaerts MY. A prospective study of soft- and hard-tissue changes after mandibular advancement surgery: Midline changes in the chin area. *Am J Orthod Dentofacial Orthop*. 2020 May;157(5):662-667. doi: 10.1016/j.ajodo.2019.05.022. PMID: 32354439.