

## Paraurethral cyst in adult women: A case report

Abidine Lkbir \*, Manal Mekouar, Mustapha Raboua, Btissam Zouita, Dounia Basraoui and Hicham Jalal

*Department of Radiology, Mother and Child Hospital, University Hospital of Mohamed VI.*

World Journal of Advanced Research and Reviews, 2024, 24(03), 145–147

Publication history: Received on 17 October 2024; revised on 30 November 2024; accepted on 02 December 2024

Article DOI: <https://doi.org/10.30574/wjarr.2024.24.3.3603>

### Abstract

The paraurethral cyst in adult women rarely reported in the literature. Its pathogenesis is confused with that of suburethral diverticula. Its treatment is not well codified. We report a case of cyst paraurethral in a young woman of 32 years. We discuss the clinical, diagnostic and therapeutic aspects of this rare entity through a review of the literature.

**Keywords:** Paraurethral; Cyst; MRI; Diverticulum

### 1. Introduction

The paraurethral cyst is different from the suburethral diverticulum and considerably less frequent. Due to their most often asymptomatic nature, it is rarely diagnosed and treated. However, the presence of this paraurethral cyst can cause urogenital signs. Symptomatic cysts are an indication for surgical treatment. We report a case of a paraurethral cyst in a 32-year-old young woman and discuss the clinical, diagnostic and therapeutic aspects of this rare entity through a review of the literature.

### 2. Observation

32 year old patient, 4 children born alive by vaginal delivery; The patient in the history had reported a repeated genital infection treated which was made up of fetid leucorrhea chronic pelvic pain with dysuria. On gynecological examination: normal cervix intact anterior vaginal wall, no visible fistula. On vaginal examination; swelling protruding into the anterior vaginal wall by 2cm.

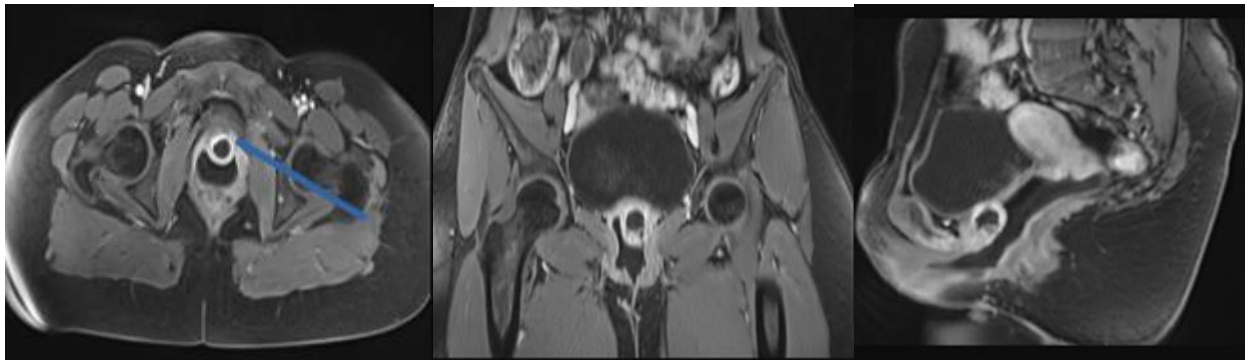
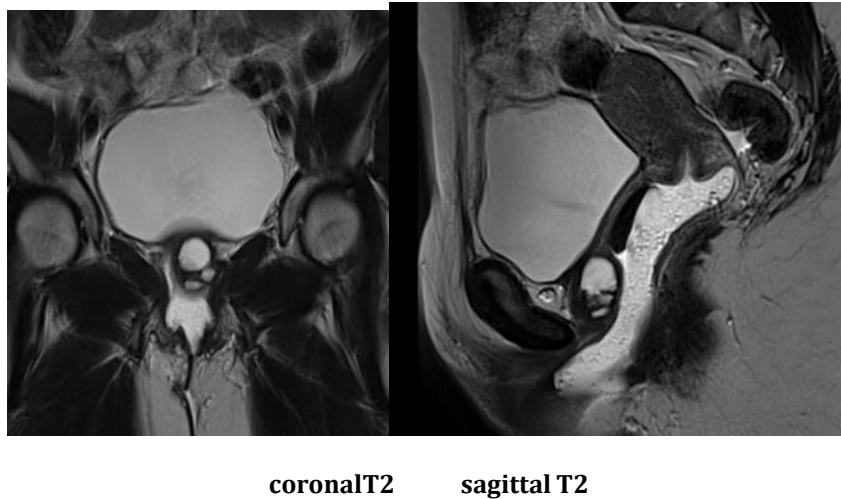
Pelvic MRI shows the presence of a subvesical formation of 20x22mm in T2 hypersignal, T1 hyposignal, limited in front by the urethra and behind by the anterior wall of the vagina in which it protrudes. The mass is limited by a regular wall which takes up the contrast intensely.

### 3. Discussion

A paraurethral cyst is rarely reported in the literature. This cyst is different from the diverticulum clinically, diagnostically and therapeutically. The pathogenesis may be the same but not documented in the current literature given its rarity. Several hypotheses have been put forward, congenital, iatrogenic, traumatic and especially infectious. The signs observed in case of paraurethral cyst in the literature are: sensation of mass, dyspareunia, dysuria, periodic pain in the region of the external genitalia. The diagnosis is confirmed thanks to the data of the ultrasound and especially of the MRI. It is noted that some cases of paraurethral cyst have been reported in infants. The few rare cases reported in the literature propose surgical treatment for symptomatic paraurethral cysts.

\* Corresponding author: A. Lkbir

### 3.1. MRI pelvis



**Figure 1** Pelvic MRI sections axial, coronal and sagittal in T1 after injection of contrast product and fat saturation

subvesical formation of 20x22mm in T2 hypersignal, T1 hyposignal, limited in front by the urethra and behind by the anterior wall of the vagina suggesting a paraurethral cyst.

---

### 4. Conclusion

Paraurethral cyst is rare, its diagnosis is confused with suburethral diverticula on clinical examination. Urogenital infection seems to be the cause. The few rare cases reported in the literature suggest surgical treatment for symptomatic paraurethral cysts.

---

### Compliance with ethical standards

#### *Disclosure of conflict of interest*

No conflict of interest to be disclosed.

#### *Statement of informed consent*

Informed consent was obtained from all individual participants included in the study.

---

### References

- [1] Tomasz konecki, Maciej Salagierski, Marek Sosnowski. Treatment of paraurethral cysts in female patients- description of three cases. Central European Journal of Urology. 2009 Jun;62(2): 111-113. PubMed | Google Scholar
- [2] Marshall S. Urethral diverticula in young girls. Urology. 1981 Mar;17(3):243-245. PubMed | Google Scholar

- [3] Diabate I, Sow I. Female urethral diverticulum containing multiple calculi. *Prog urol*. 2011Mar;21(3):229- 232. PubMed | Google Scholar
- [4] Routh A. Urethral diverticulum. *Br Med J*. 1890; 1:360-365. PubMed | Google Scholar
- [5] Isen K, Utku V, Atilgan I, Kutun Y. Experience with the diagnosis and management of paraurethral cysts in adult women. *The Canadian journal of urology*. 2008 Sep;15(4):4169-73. PubMed | Google Scholar Page number not for citation purposes 4
- [6] Ceylan H, Ozokutan BH, Karakok M, Buyukbese S. Paraurethral cyst: is conservative management always appropriate? *European journal of pediatric surgery*. 2002 Jul;12(3):212-4. PubMed | Google Scholar.